

Case 65

Acute abdomen in a medical student

A first year medical student was taken to the Emergency Department of her teaching hospital by a fellow student in her digs. She was seen promptly by a specialist registrar, who obtained the following history. She was quite well until the early hours of that morning, when she was woken up by central, dull, abdominal pain. This got worse as the morning went on and she vomited some of her last night's supper and then some greenish fluid. She then found that the pain had worsened and was now more in her lower right abdomen, was much worse and hurt her if she moved around in bed – she was best off lying on her side, keeping as still as possible and with her knees bent up.

Her bowels had moved normally the day before, but not since the pain began. Her periods were normal, the last a fortnight before, and there were no urinary symptoms. Apart from chickenpox as a child, she had always been well. She had never had a pain like this before.

On examination, the registrar found that she looked flushed and apprehensive. Her tongue was heavily coated and she had foetor oris. Her temperature was 38.0°C and pulse 96 beats/min. She was reluctant to move on the trolley, and gingerly shifted herself to lie on her back, but with her knees raised. The abdomen was not distended, but there was marked tenderness in the right iliac fossa with rigidity of the abdominal wall in this area. Bowel sounds were heard, but only after listening for a couple of minutes with a stethoscope.

A rectal examination showed marked tenderness anteriorly, but no masses were felt. A routine urine examination was normal, including microscopy. A full blood count was sent off, which showed a white cell count total of $13.0 \times 10^9/L$ with a polymorph leucocytosis. A pregnancy test was negative.

This sounds like a 'barn door' case of acute appendicitis and would be the obvious one to make, but what other possibilities enter into your differential diagnosis?

There is a wide spectrum of causes of any abdominal pain

– here we will concentrate on the right iliac fossa. Any experienced clinician will tell you that you will encounter many, if not all, of them during your career. Consider the anatomical structures that might be involved and then the possible pathologies affecting them, for example:

- Terminal ileum: Crohn's disease, Meckel's diverticulitis.
 - Caecum: Carcinoma (in older subjects), solitary diverticulum.
 - Mesentery: Mesenteric adenitis.
 - Gallbladder: A distended inflamed gallbladder can project downwards into the right iliac fossa.
 - Female pelvic organs: Salpingitis, ectopic pregnancy, twisted ovarian cyst.
 - Genitourinary tract: Ureteric colic from stone, acute pyelonephritis, referred pain from testis (obviously not in this case). Consider also referred pain from the chest (basal pleurisy) or CNS (prodromal herpes zoster).
- A wise saying is that nothing can be so easy, or so difficult, as the diagnosis of appendicitis!

Does the presence of pus cells in the urine exclude the diagnosis of acute appendicitis? What about the value of a white cell count?

- Although pus cells in the urine suggest a urinary tract infection, an inflamed appendix adherent to the ureter or the bladder may produce microscopic pyuria or haematuria.
- Although the majority of cases of acute appendicitis will have a moderate leucocytosis with predominance of polymorphs, the count may be entirely normal.

Having made a clinical diagnosis, the registrar called the surgeon on take who agreed with the findings, and urgent surgery was deemed necessary. What are the preoperative measures?

- Reassurance.

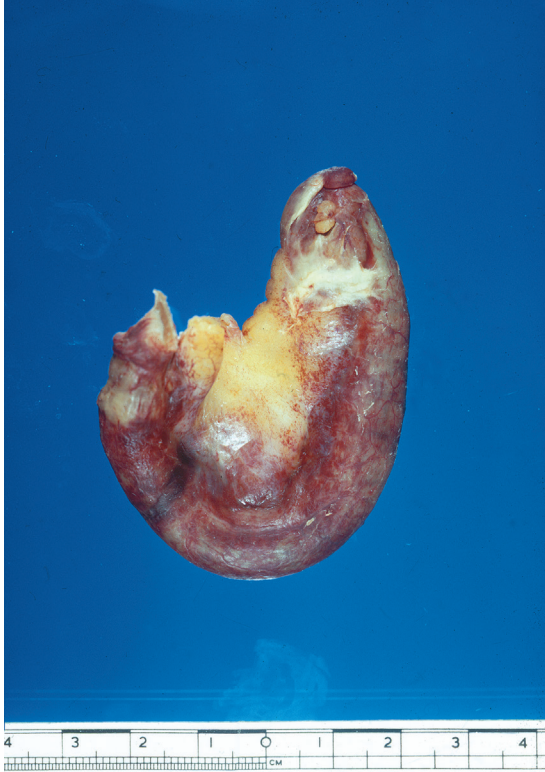


Figure 65.1 Excised inflamed appendix.

- Premedication: an injection of opiate analgesia combined with an anti-emetic would be reasonable.

- Commence antibiotic cover, e.g. metronidazole, which can be given as a rectal suppository.

The diagnosis was confirmed at laparoscopy 2 h later, and an acutely inflamed appendix removed (Fig. 65.1).

Left untreated, what might have happened to the patient?

One of three things:

- The acutely inflamed appendix might have become gangrenous and progressed to perforate freely into the peritoneal cavity, producing a general peritonitis.
- The appendix might become walled off to form an appendix mass (see Case 66, p. 133).
- The inflammatory process might resolve, although there is a strong chance of a further attack of appendicitis. It is not uncommon for a patient with acute appendicitis to give a history of having had a similar, although milder, attack weeks or even some months before this episode.

What clinical features would suggest that the acutely inflamed appendix had perforated into the peritoneal cavity?

The temperature and pulse are raised, the patient is flushed and toxic, the abdomen is diffusely tender, with rigidity of the abdominal muscles and with absent bowel sounds – i.e. the clinical picture of a diffuse peritonitis.

Fortunately this medical student made a smooth recovery from her operation and spent her convalescence revising the anatomy of the abdomen.